

## PEDIATRIC CHALAZION CASE REPORT

By Liem H. Nguyen, BS, Edward H. Jaccoma, MD

Corresponding Author: [lnguyen11@une.edu](mailto:lnguyen11@une.edu)

Submitted: June 26, 2018. Accepted: November 22, 2018. Published: December 28, 2018.

---

### ABSTRACT

#### Background and Objectives

A chalazion, also known as a sty, is a common and chronic inflammatory problem of the eyelids where one or more Meibomian glands are blocked. Previous studies have shown that a chalazion is a sign of Meibomian Gland Dysfunction (MGD) and evaporative dry eye disease. The prevalence of chalazia in the pediatric population has recently been noted. In this report, we will describe two pediatric cases of chalazion that are associated with MGD and related dry eye disease.

#### Methods

This is a case report of non-genetically related 7-year-old and 16-year-old patients as they were each seen for newly developed chalazia.

#### Results

External exam in both patients showed chalazia, waxy plugs and poor Meibomian gland expression. Meibography showed shorten, truncated, and dilated Meibomian glands with rapid tear break-up times leading to the diagnosis of evaporative dry eye disease due to MGD.

#### Conclusion

These cases serve to confirm an increase in the prevalence of MGD in the pediatric population and to emphasize the need for early screening for dry eye disease.

**Key Words:** Chalazion, Meibomian gland dysfunction, Pediatric Dry Eye Disease

Chalazia are a common eye disease in which there is granulomatous inflammatory growth in the upper or lower eye lid.<sup>1</sup> The primary cause of a chalazion is obstructive Meibomian gland dysfunction (MGD).<sup>2</sup> Meibomian glands are holocrine, sebaceous glands that secrete lipids containing cholesterol, wax esters, triacylglycerol, free fatty acids, and phospholipids. These secretions spread onto the tear film through full blinks, promoting tear-film stability and retarding evaporation. Dysfunction of these glands will destabilize the tear film and increase evaporation of tears. Therefore, MGD is considered the most frequent cause of evaporative dry eye disease.<sup>3,4</sup>

A recent study from Duke University has shown a range from mild to moderate/ severe MGD in 78% of patients in a population of 99 participants aged 4 to 17 years.<sup>5</sup> This may correlate to the increase in screen time, which yields weak and partial blinks as well as the increased consumption of processed (fast) foods in the younger generation. A good blink, which consists of a full eyelid movement, allows the orbicularis muscle on the external side of the tarsal plate to compress the Meibomian glands (Muscle of Riolan). This compression will promote secretions of the Meibomian glands onto the ocular surface.<sup>6</sup> Failure to practice good blinks or absence of blinking will accumulate meibum within the ductal system. This prolonged accumulation of secretion can lead to dilated, clogged glands, and allow the action of common skin flora to interact with these stagnant secretions, creating waxy blockages and swollen lid margin tissues leading to obstruction. This is the typical prequel of what clinically is referred to as a chalazion.<sup>6</sup> Obstructive MGD subsequently leads to retaining the oily secretions, which can leak into adjacent tissue. This can lead to formation of the chronic granulomatous inflammation that is the pathological basis for a chalazion. In this report, we present two pediatric cases of chalazion that are associated with MGD and related evaporative dry eye disease.

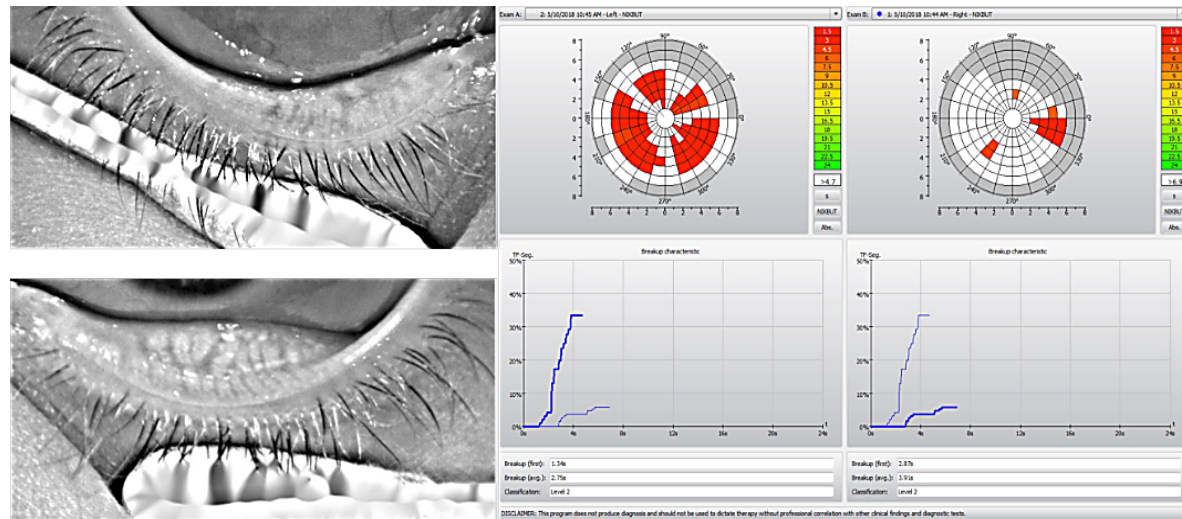
Note that we use the validated 5-point meiboscale for gland atrophy for grading that was also used in the Duke study.<sup>10</sup> The scale is as follows: grade 0: normal Meibomian glands, grade 1:  $\leq 25\%$  gland atrophy, grade 2: 26% to 50% gland atrophy, grade 3:

51% to 75% gland atrophy, and grade 4:  $>75\%$  gland atrophy. The scale reported by Arita et al., which is a 3-point scale with distortion/tortuosity defined as a  $>45$ -degree angle of the Meibomian gland, was also used to grade the tortuosity of patient's Meibomian glands in the Duke study and in our report: grade 0: no distortion, grade 1: 1 to 4 glands distorted, and grade 2: 5 or more glands distorted.<sup>11</sup>

## CASE REPORT

A 7-year-old female patient was seen for a new chalazion affecting the right upper eyelid the past week and history of earlier chalazia in the left upper eyelid. Previously, she had an incision and drainage procedure done by a pediatric ophthalmologist about 1 year before, with the diagnosis of "Pediatric Rosacea." Her pediatrician noted a history of frequent hordeolum and chalazion formation. Past medical history includes mild asthma, which was resolved a year ago, and allergy to amoxicillin. Review of systems was negative excepting a sense of dry eye that was treated with twice daily use of Blink artificial tears. She had been using Polytrim drops O.D. to help with the chalazion of the right upper eyelid. In addition, she was on 5 mg of cetirizine for allergies, metronidazole 0.75% cream B.I.D, Flovent puffs B.I.D., and ProAir puffs every 6 hours. Social history was pertinent as this patient, per discussion with her father to her pediatrician, was a "picky eater," but ate from all food groups, and favoured almond milk. She ate 3 servings of fruit and veggies per day and typically had one fast food meal per week. She had 2 hours for recreational screen time, actively played for about 1.5 hour, and slept 10 hours per day. She had a TV with Internet connection in her bedroom. Her uncorrected visual acuity was 20/25- O.D. and 20/20- O.S. External exam showed mild epicanthal folds O.U. We noted chronic chalazia of the right upper and left upper eyelids. Maddarosis and crusting were noted along with many Meibomian gland orifice waxy plugs and poor Meibomian gland expression by Q-tip compression. Also, she had mild conjunctival injection with rapid non-invasive tear break-up times (TBUTs) of 1.34 seconds O.D. and 2.87 seconds O.S. to first breakup by Oculus 5M, truncated and dilated Meibomian

**FIGURE 1.** The 7-year-old patient’s meibograph and non-invasive tear break-up time report.



glands, and regular partial blinks of both eyes of  $\frac{1}{3}$  blinks O.D. and  $\frac{4}{5}$  O.S. blinks per 20 seconds/eye on LipiView testing (Figure 1). Her meiboscale for gland atrophy is grade 1 and her Meibomian gland tortuosity is also grade 1 O.U.

A 16-year-old female patient was also seen for a new chalazion affecting her right upper eyelid for several months. She stated that it was not painful and there had been no drainage or swelling. She admitted to 5–6 hours of screen time per day and a recent weight loss from changing her diet, which previously included “a lot of junk food.” She had no specific dry eye complaints and was in good health. Her visual acuity was 20/20- O.D. and 20/25 O.S. External exam showed a medium sized chalazion of her RUL, along with many meibomian orifice waxy plugs with poor expression by Q-tip compression. Also, she had mild lid margin crusting, with signs of blepharitis and conjunctival injection. There was a rapid non-invasive TBUT of 3.82 seconds O.D. and 7.26 seconds O.S. to first breakup by Oculus 5M. Meibography showed short, dilated and truncated meibomian glands. Lastly, she also had regular partial blinks of both eyes with the Lipiview measuring  $\frac{2}{3}$  blinks O.D. and  $\frac{4}{6}$  blinks O.S. in 20 seconds (Figure 2). Her meiboscale for

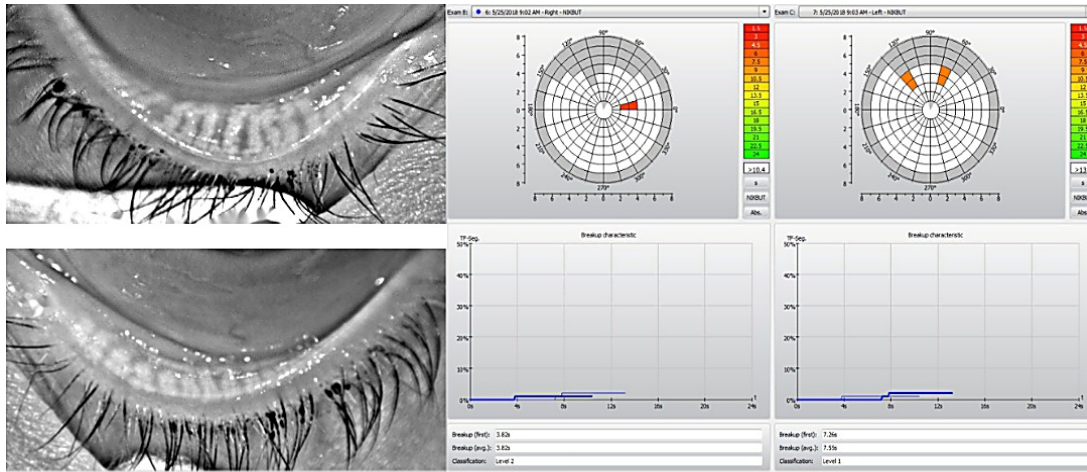
gland atrophy is grade 1 O.D. and grade 2 O.S. and her meibomian gland tortuosity is grade 0.

## DISCUSSION

In our patients, the presence of a chalazion can be seen as the first sign of obstructive Meibomian gland dysfunction.<sup>2</sup> Although the 16-year-old patient didn’t have any complaint for symptoms of dry eye while the 7-year-old patient was already using Blink artificial tears twice daily, meibography showed dysfunctional, clogged, truncated, shortened and heavily inspissated Meibomian glands in both patients. This clinical presentation is associated with evaporative dry eye disease in previous studies.<sup>3,4</sup> If left untreated, it can lead to irreversible gland atrophy, which makes treatment of the associated dry eye disease a lot more challenging.<sup>9</sup>

The clinical presentation of a chalazion, or a sty, is often overlooked by healthcare professionals since it is usually self-resolved. However, it can be a sign of one or many obstructed Meibomian glands. Therefore, it is important to get a comprehensive dry eye disease evaluation that ideally consists of measuring tear meniscus height, bulbar redness, tear osmolarity, tear break-up time, Schirmer’s values, and more

**FIGURE 2.** 16-year-old patient’s meibograph and non-invasive tear break-up time report.



importantly, acquiring good meibography to look for early signs of MGD. Early diagnosis should allow early intervention that is less costly and more effective.

### CONCLUSIONS

These cases serve to confirm an increase in the prevalence of MGD in the pediatric population and to emphasize the need for early screening for dry eye disease.

### ACKNOWLEDGEMENTS

I thank Dr. Jaccoma, MD, who provided help in writing and revising the manuscript.

### REFERENCES

1. Mueller JB, McStay CM. Ocular infection and inflammation. *Emerg Med Clin North Am.* 2008;26(1):57–72, vi.
2. Nelson JD, Shimazaki J, Benitez-del-Castillo JM, et al. The international workshop on meibomian gland dysfunction: report of the definition and classification subcommittee. *Invest Ophthalmol Vis Sci.* 2011;52(4):1930–1937.
3. Bron AJ, Tiffany JM. The contribution of meibomian disease to dry eye. *Ocul Surf.* 2004;2:149–165.
4. Heiligenhaus A, Koch JM, Kemper D, Kruse FE, Waubke TN. [Therapy in tear film deficiencies]. *Therapie von*

- Benetzungsstörungen. *Klin Monatsbl Augenheilkd.* 1994;204:162–168.
5. Gupta PK, Stevens MN, Kashyap N, Priestley Y. Prevalence of Meibomian Gland Atrophy in a Pediatric Population. *Cornea.* 2018;37(4):426–430. doi:10.1097/ICO.0000000000001476.
6. Linton RG, Curnow DH, Riley WJ. The meibomian glands: An investigation into the secretion and some aspects of the physiology. *Br J Ophthalmol.* 1961;45:718–723.
7. Tiffany J M, Dart J K G. Normal and abnormal functions of meibomian gland secretions. *Roy Soc Med Int Cong Symp Ser* 1981;40:1061-4. [0067]
8. Arita R, Itoh K, Inoue K, Kuchiba A, Yamaguchi T, Amano S. Contact lens wear is associated with decrease of meibomian glands. *Ophthalmology.* 2009;116:379–384
9. Straatsma BR. Cystic Degeneration of the Meibomian Glands. *AMA Arch Ophthalmol.* 1959;61:918–927.
10. Pult H, Riede-Pult B. Comparison of subjective grading and objective assessment in meibography. *Cont Lens Anterior Eye.* 2013;36:22–27.
11. Arita R, Itoh K, Maeda S, et al. Association of contact lens-related allergic conjunctivitis with changes in the morphology of Meibomian glands. *Jpn J Ophthalmol.* 2012;56:14–19.